



**PATIENT**

Kelly Dubois

**SPECIES**

Canine

**BREED**

Cocker Spaniel

**SEX**

Female Spayed

**AGE**

7 years

**WEIGHT**

20lbs

**INTERPRETED BY**

Maggie Machen  
Lamy, DVM  
DACVIM (Cardiology)

**IMAGING PERFORMED BY**

Pamela Harrigan,  
RDCS

**HOSPITAL NAME**

Firehouse Veterinary  
Clinic

**REFERRING VET**

Dr. Fleming

**INVOICE**

28351

**DATE**

1/16/23

**PRESENTING CLINICAL SIGNS**

History: Recheck echo. History trivial MR-query normal variant (mitral value appeared normal)- on prior echocardiogram 10/6/20 (Nate Deering, DVM, DACVIM-Cardiology). History low grade 2nd degree AV block (Mobitz type 1)- physiologic/normal variation. Presently, doing well at home with no clinical issues. No medications.  
-Previous echo measurements: LA 2.0cm, LA:Ao 1.31, LV 2.7 cm. \*No sedation for study.

**ECHOCARDIOGRAM FINDINGS**

2D, m-mode, color flow and Doppler imaging is available.

**Left ventricle:** The LV diameter is normal with adequate myocardial function. LV wall thicknesses are normal.

**Left atrium:** The left atrium is mildly dilated.

**Mitral valve:** The mitral valve is diffusely thickened with no prolapse into the left atrial lumen. Trace mitral regurgitation.

**Aortic valve/aorta:** The aortic valve is normal in morphology and mobility. Normal aortic outflow velocity; laminar flow. No aortic insufficiency.

**Right ventricle:** Normal right ventricular diameter and morphology indicating no overt evidence of pulmonary arterial hypertension.

**Right atrium:** Normal RA dimension.

**Tricuspid valve:** The tricuspid valve appears mildly thickened with minimal septal prolapse. Mild tricuspid regurgitation; normal velocity.

**Pulmonic valve/pulmonary artery:** The pulmonic valve is normal in morphology and mobility. No pulmonic insufficiency. Normal RVOT velocity; laminar flow.

**Pericardium/other:** No pericardial or pleural effusion noted. No obvious cardiac masses.

**Heart rhythm:** ECG reveals a sinus rhythm with an average HR of 120bpm.

**2-Dimensional Measurements**

Ao diam (cm)	1.4
LA diam (cm)	1.8
LA:Ao (Swe)	1.3
IVS thickness (cm)	0.7
LVID diastole (cm)	2.7
PW thickness (cm)	0.7
LVID systole (cm)	1.3
FS (%)	50

**Doppler Measurements**

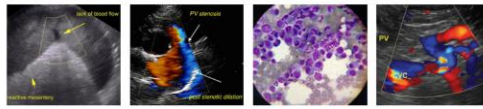
PV Vmax (m/s)	1.0
AoV Vmax (m/s)	1.67
MR Vmax (m/s)	NM
TR Vmax (m/s)	1.9
TR PG (mmHg)	15

**INTERPRETATION OF THE FINDINGS**

Chronic degenerative valve disease is suspected, with trace mitral and mild tricuspid regurgitation. Lack of significant left atrial enlargement indicates the current risk for complication is low. No concurrent issues such as systolic dysfunction or pulmonary hypertension are noted in this study. Assessment of progression in the future will help predict long term prognosis, which is highly variable at this stage (B1). Findings appear similar to the prior results.

**RECOMMENDATIONS**

- In an asymptomatic dog without significant left atrial enlargement, no cardiac medications are clearly indicated.



**PATIENT**

Kelly Dubois

**SPECIES**

Canine

**BREED**

Cocker Spaniel

**SEX**

Female Spayed

**AGE**

7 years

**WEIGHT**

20lbs

**INTERPRETED BY**

Maggie Machen  
 Lamy, DVM  
 DACVIM (Cardiology)

**IMAGING**

**PERFORMED BY**

Pamela Harrigan,  
 RDCS

**HOSPITAL NAME**

Firehouse Veterinary  
 Clinic

**REFERRING VET**

Dr. Fleming

**INVOICE**

28351

**DATE**

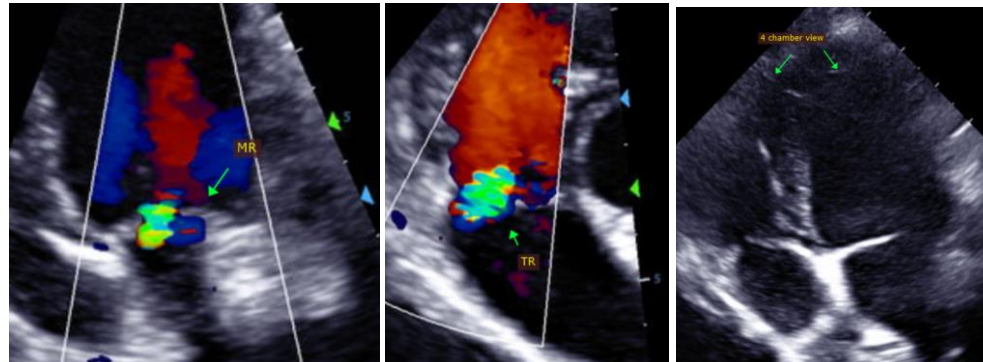
1/16/23

- Omega fatty acid supplementation and mild salt restriction may be of some long-term benefit.
- Anesthetic risk is considered mild if needed. Cardiac protective drug choices (opioid/benzodiazepine premedication, propofol or alfaxalone induction, isoflurane gas) are recommended. Pre-oxygenate for 5-10 minutes prior to induction. Monitor for arrhythmias, hypotension, and hypoxia both intra and post-operatively and intervene as necessary. Mild IV fluid restriction is recommended to avoid fluid overload. Avoid heart rate stimulating drugs such as atropine unless clinically indicated.
- Monitor for development of a cough, labored breathing, exercise intolerance or collapse episodes.

**PLAN**

- Recommend conservative monitoring with a recheck echocardiogram in 6-12 months, sooner if any development of clinical signs.

**IMAGES**



The information and recommendations provided are based on the images presented by the referring veterinarian. No evaluation can be communicated regarding pathology that was not visible in the image/video clips provided.

Thank you for this referral. This report was generated using transcription software, and minor dictation errors may be present. If the clinical or image interpretation does not parallel your findings or if I can be of any further assistance, please contact me.

**Maggie Machen Lamy, DVM**  
 Diplomate of the American College of Veterinary Internal Medicine (Cardiology)  
[info@sonopath.com](mailto:info@sonopath.com)

Echocardiogram performed by: Pamela Harrigan, RDCS  
 Pet Animal Ultrasound Service ([4paus.com](http://4paus.com))